ISSN : 2321-3841

Journal of Oral and Maxillofacial Radiology

May-August 2019 • Issue 2 • Volume 7
www.joomr.org

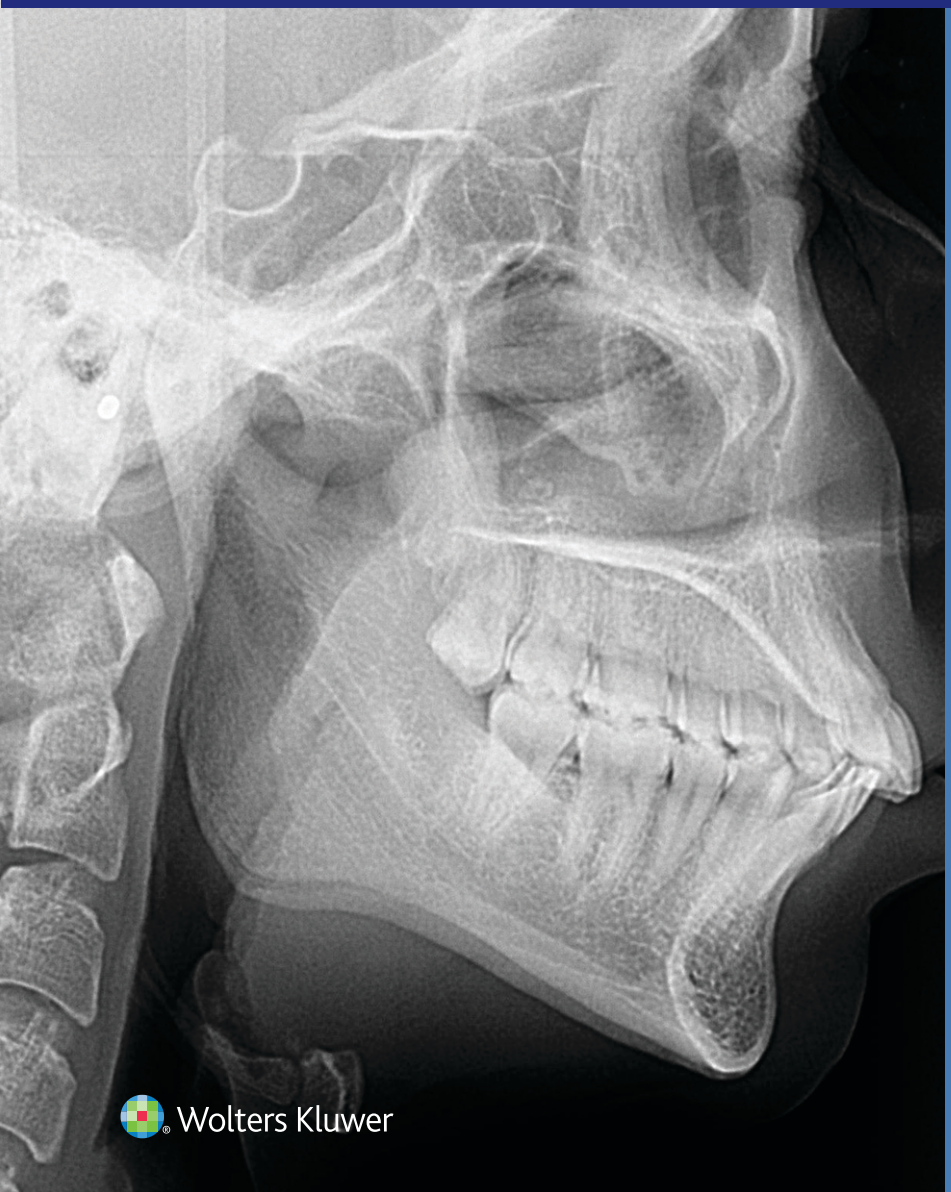

Wolters Kluwer
Medknow

Original Article

Characteristics of the patients with temporomandibular joint effusion on magnetic resonance imaging

Ichiro Ogura, Fumi Mizuhashi[1], Yoshihiro Sugawara[2], Makoto Oohashi[3], Hirokazu Sekiguchi[4], Hisato Saegusa[2]

Department of Oral and Maxillofacial Radiology, [1]Department of Removable Prosthodontics, The Nippon Dental University School of Life Dentistry at Niigata, Niigata, [2]Comprehensive Dental Care, [3]Dental Anesthesia and General Health Management, [4]Laboratory of Dental Technology, The Nippon Dental University Niigata Hospital, Niigata, Japan

ABSTRACT

Background: Magnetic resonance imaging (MRI) is widely used in the region of temporomandibular joint (TMJ), particularly to examine disc position and configuration, posterior disc attachment, and mandibular marrow status and to assess the presence of TMJ effusion. **Aims:** The aim of this study is to investigate the characteristics of the patients with TMJ effusion on MRI. **Materials and Methods:** MR images of 98 TMJs of 49 patients with temporomandibular disorders were evaluated in this study. The patients with TMJ effusion were concerning age, gender, TMJ pain, disc displacement with or without reduction, and osteoarthrosis. **Results:** The incidence of the patients with TMJ effusion was significantly different between male (19.2%) and female (51.4%, $P = 0.005$) and between TMJ pain present (53.7%) and absent (29.5%, $P = 0.024$), respectively. Logistic multivariate regression analysis demonstrated that gender (odds ratio = 4.188, $P = 0.012$) and TMJ pain (odds ratio = 2.704, $P = 0.027$) were significant in patients with TMJ effusion. **Conclusions:** This study suggests that characteristics of the patients with TMJ effusion include female and TMJ pain.

Key words: Disc displacement, joint effusion, magnetic resonance imaging, osteoarthrosis, temporomandibular joint imaging

INTRODUCTION

Many studies had been carried out to evaluate the morphological differences in the temporomandibular joint (TMJ) to develop diagnosis and treatment of temporomandibular disorders (TMDs).[1] TMDs represent a major cause of nondental pain in the orofacial region and are considered to be a subclass of musculoskeletal disorders.[2] Internal derangement of TMJ is the most common cause of TMD. It describes an abnormal position of the articular disc.[3]

Magnetic resonance imaging (MRI) is an advanced imaging technique that provides excellent contrast in soft tissues without radiation or surgical invasion. MRI is widely used in the region of TMJ, particularly to examine disc position and configuration, posterior disc attachment, and mandibular marrow status and to assess the presence of TMJ effusion.[4-11]

Furthermore, TMJ effusion, which typically appears as a bright signal on T2-weighted MR images,[4] has been

Access this article online	
Quick Response Code:	Website: www.joomr.org
	DOI: 10.4103/jomr.jomr_20_19

Cite this article as: Ogura I, Mizuhashi F, Sugawara Y, Oohashi M, Sekiguchi H, Saegusa H. Characteristics of the patients with temporomandibular joint effusion on magnetic resonance imaging. J Oral Maxillofac Radiol 2019;7:30-3.

Address for correspondence: Prof. Ichiro Ogura, Department of Oral and Maxillofacial Radiology, The Nippon Dental University School of Life Dentistry, 1-8 Hamaura-Cho, Chuo-Ku, Niigata, Niigata 951-8580, Japan.
E-mail: ogura@ngt.ndu.ac.jp

recognized as a possible sign related to pain in patients with TMD.[6,8,12-14] However, some authors question the relationship.[15-18] Other factors correlated with either TMJ effusion or pain could influence the relationship. The status of the disc in the TMJ could be one of the factors as it has been correlated with TMJ effusion as well as with pain.[8]

However, to the best of our knowledge, the characteristics of the patients with TMJ effusion on MRI have not been reported in the literature. The aim of this study is to investigate the characteristics of the patients with TMJ effusion on MRI.

Materials and Methods

Patients

This study was approved by the ethics committee of our institution. After providing written informed consent, 49 patients (13 males and 36 females; age 14–85 years, mean age 46.3 years) with TMDs underwent MRI at our university hospital from October 2018 to March 2019.

Magnetic resonance imaging techniques

The MR images (1.5 Tesla MR unit; EXCELART Vantage MRT-2003; Canon Medical Systems, Otawara, Japan) with a surface coil for the TMJ included proton density-weighted sagittal and coronal imaging at the closed mouth position and the maximum mouth opening position (repetition time [TR]/echo time [TE] 2000 ms/18 ms, field of view [FOV] 130 mm × 130 mm, matrix size 256 × 224, and 1 acquisition) and T2-weighted sagittal and coronal imaging at the closed mouth position and the maximum mouth opening position (TR/TE 3500 ms/100 ms, FOV 130 mm × 130 mm, matrix size 256 × 192, and 2 acquisitions).

Data analysis

All MR images of 98 TMJs of 49 patients with TMD, such as disc displacement with or without reduction, TMJ effusion, and osteoarthrosis, were independently evaluated by two oral radiologists, and any differences were resolved by forced consensus using criteria of the image findings.[10,12] The patients with TMJ effusion were concerning age, gender, TMJ pain, disc displacement with or without reduction, and osteoarthrosis.

Statistical analysis

Statistical analyses for characteristics of the patients with TMJ effusion were performed using the Chi-square test with Fisher's exact test. The odds ratios for the characteristics of the patients with TMJ effusion were analyzed using logistic multivariate regression analysis. These analyses were performed with the statistical package IBM SPSS statistics version 24 (IBM Japan, Tokyo, Japan). A $P < 0.05$ was considered statistically significant.

Results

The characteristics of the patients with TMJ effusion on MRI are shown in Table 1. The incidence of the patients with TMJ effusion was significantly different between male (19.2%) and female (51.4%, $P = 0.005$) and between TMJ pain present (53.7%) and absent (29.5%, $P = 0.024$), respectively. Furthermore, logistic multivariate regression analysis demonstrated that gender (odds ratio = 4.188, $P = 0.012$) and TMJ pain (odds ratio = 2.704, $P = 0.027$) were significant in patients with TMJ effusion [Table 2]. Figure 1 indicates a patient with TMJ pain, effusion, and disc displacement without reduction on MRI.

Table 1: Characteristics of the 49 patients with temporomandibular joint effusion on magnetic resonance imaging

Characteristics	Number of TMJs (*n*=98)	TMJ effusion on MRI		*P*
		With (*n*=42), *n* (%)	Without (*n*=56), *n* (%)	
Age (years)				
≤50	52	25 (48.1)	27 (51.9)	0.310
>50	46	17 (37.0)	29 (63.0)	
Gender				
Male	26	5 (19.2)	21 (80.8)	0.005
Female	72	37 (51.4)	35 (48.6)	
TMJ pain				
Present	54	29 (53.7)	25 (46.3)	0.024
Absent	44	13 (29.5)	31 (70.5)	
MRI findings				
Disc displacement				
With reduction	61	24 (39.3)	37 (60.7)	0.405
Without reduction	37	18 (48.6)	19 (51.4)	
Osteoarthrosis				
Present	28	12 (42.9)	16 (57.1)	1.000
Absent	70	30 (42.9)	40 (57.1)	

TMJs: Temporomandibular joints; MRI: Magnetic resonance imaging

Table 2: Logistic multivariate regression analysis in patients with temporomandibular joint effusion on magnetic resonance imaging

Characteristics	OR	95% CI	*P*
Age (>50 years)	0.826	0.340-2.007	0.673
Gender (female)	4.188	1.362-12.879	0.012
TMJ pain	2.704	1.120-6.530	0.027
MRI findings			
Disc displacement without reduction	1.518	0.488-4.724	0.471
Osteoarthrosis	0.700	0.208-2.356	0.565

TMJ: Temporomandibular joint; MRI: Magnetic resonance imaging; OR: Odds ratio; CI: Confidence interval

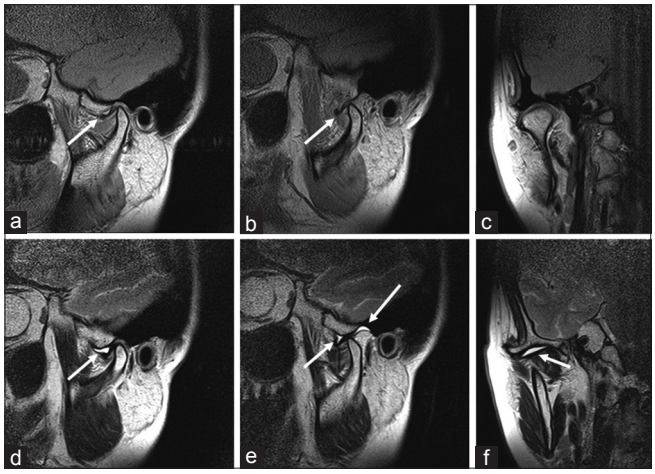

Figure 1: Magnetic resonance imaging of the right temporomandibular joint in a 28-year-old female with temporomandibular disorders. (a and c) Proton density-weighted sagittal and coronal oblique cross section imaging at the closed mouth position (arrow: Disc displacement). (b) Proton density-weighted sagittal oblique cross-section imaging at the maximum mouth opening position. (d and f) T2-weighted sagittal and coronal oblique cross-section imaging at the closed mouth position (arrow: Temporomandibular joint effusion). (e) T2-weighted sagittal oblique cross-section imaging at the maximum mouth opening position (arrow: Temporomandibular joint effusion)

Discussion

The authors found that characteristics of the patients with TMJ effusion include female and TMJ pain. Some authors have compared TMJ effusion, the MR finding of a hyperintense signal inside the joint space, in painful and nonpainful TMJs and found a significant association between TMJ pain and increased signal intensity.[7,18,19] However, other authors have disclosed that the TMJ effusion did not directly relate to the presence of TMJ pain.[15,20] Further, Adame *et al*.[16] failed to relate TMJ pain and TMJ effusion; they depicted TMJ effusion as being related to the MR findings of internal derangement and osteoarthrosis. In this study, we showed that the incidence of the patients with TMJ effusion was not significantly different between disc displacement with reduction (39.3%) and without reduction (48.6%, $P = 0.405$) and between osteoarthrosis present (42.9%) and absent (42.9%, $P = 1.000$), respectively.

Regarding logistic multivariate regression analysis in TMJ pain, Emshoff *et al*.[21] showed that significant increases in risk of TMJ pain occurred with disc displacement without reduction in combination with osteoarthrosis and bone marrow edema (3.7:1 odds ratio) and with disc displacement without reduction in combination with osteoarthrosis and effusion (2.8:1 odds ratio). Ogura[12] indicated a significant relationship between TMJ pain during maximum jaw opening and disc displacement without reduction (odds ratio = 2.36), TMJ effusion (odds ratio = 2.24), gender (odds ratio = 1.58), and osteoarthrosis (odds ratio = 1.40). In this study, logistic multivariate regression analysis demonstrated that gender (odds ratio = 4.188, $P = 0.012$) and TMJ pain (odds ratio = 2.704, $P = 0.027$) were significant in patients with TMJ effusion. Therefore, we consider that characteristics of the patients with TMJ effusion include female and TMJ pain.

There were several limitations of this study. The sample was relatively small. Therefore, further research is necessary to validate these results.

Conclusions

We investigated the characteristics of the patients with TMJ effusion on MRI. The results suggest that characteristics of the patients with TMJ effusion include female and TMJ pain.

Declaration of patient consent

The authors certify that they have obtained all appropriate patient consent forms. In the form the patient(s) has/have given his/her/their consent for his/her/their images and other clinical information to be reported in the journal. The patients understand that their names and initials will not be published and due efforts will be made to conceal their identity, but anonymity cannot be guaranteed.

Financial support and sponsorship

This work was supported by JSPS KAKENHI, Grant Number JP 18K09754.

Conflicts of interest

There are no conflicts of interest.

References

1. Soydan D, Doğan S, Canger EM, Coşgunarslan A, Akgün IE, Kış HC. Effect of internal derangements and degenerative bone changes on the minimum thickness of the roof of the glenoid fossa in temporomandibular joint. Oral Radiol 2019;28.
2. Kuttila M, Kuttila S, Le Bell Y, Alanen P. Association between TMD treatment need, sick leaves, and use of health care services for adults. J Orofac Pain 1997;11:242-8.
3. Tomas X, Pomes J, Berenguer J, Quinto L, Nicolau C, Mercader JM, *et al.*

MR imaging of temporomandibular joint dysfunction: A pictorial review. Radiographics 2006;26:765-81.
4. Harms SE, Wilk RM, Wolford LM, Chiles DG, Milam SB. The temporomandibular joint: Magnetic resonance imaging using surface coils. Radiology 1985;157:133-6.
5. Drace JE, Enzmann DR. Defining the normal temporomandibular joint: Closed-, partially open-, and open-mouth MR imaging of asymptomatic subjects. Radiology 1990;177:67-71.
6. Westesson PL, Brooks SL. Temporomandibular joint: Relationship between MR evidence of effusion and the presence of pain and disk displacement. AJR Am J Roentgenol 1992;159:559-63.
7. Sano T, Westesson PL. Magnetic resonance imaging of the temporomandibular joint. Increased T2 signal in the retrodiskal tissue of painful joints. Oral Surg Oral Med Oral Pathol Oral Radiol Endod 1995;79:511-6.
8. Larheim TA, Westesson PL, Sano T. MR grading of temporomandibular joint fluid: Association with disk displacement categories, condyle marrow abnormalities and pain. Int J Oral Maxillofac Surg 2001;30:104-12.
9. Mori S, Kaneda T, Lee K, Kato M, Motohashi J, Ogura I. T2-weighted MRI for the assessment of joint effusion: Comparative study of conventional spin-echo and fast spin-echo sequences. Oral Surg Oral Med Oral Pathol Oral Radiol Endod 2004;97:768-74.
10. Ogura I, Kaneda T, Mori S, Sakayanagi M, Kato M. Magnetic resonance characteristics of temporomandibular joint disc displacement in elderly patients. Dentomaxillofac Radiol 2012;41:122-5.
11. Kellenberger CJ, Junhasavasdikul T, Tolend M, Doria AS. Temporomandibular joint atlas for detection and grading of juvenile idiopathic arthritis involvement by magnetic resonance imaging. Pediatr Radiol 2018;48:411-26.
12. Ogura I. Magnetic resonance imaging characteristics of temporomandibular joint pain during opening and biting in patients with disc displacement. Oral Surg Oral Med Oral Pathol Oral Radiol Endod 2006;102:669-72.
13. Khawaja SN, Crow H, Mahmoud RF, Kartha K, Gonzalez Y. Is there an association between temporomandibular joint effusion and arthralgia? J Oral Maxillofac Surg 2017;75:268-75.
14. Hosgor H. The relationship between temporomandibular joint effusion and pain in patients with internal derangement. J Craniomaxillofac Surg 2019;47:940-4.
15. Murakami K, Nishida M, Bessho K, Iizuka T, Tsuda Y, Konishi J. MRI evidence of high signal intensity and temporomandibular arthralgia and relating pain. Does the high signal correlate to the pain? Br J Oral Maxillofac Surg 1996;34:220-4.
16. Adame CG, Monje F, Offnoz M, Martin-Granizo R. Effusion in magnetic resonance imaging of the temporomandibular joint: A study of 123 joints. J Oral Maxillofac Surg 1998;56:314-8.
17. Haley DP, Schiffman EL, Lindgren BR, Anderson Q, Andreasen K. The relationship between clinical and MRI findings in patients with unilateral temporomandibular joint pain. J Am Dent Assoc 2001;132:476-81.
18. Rudisch A, Innerhofer K, Bertram S, Emshoff R. Magnetic resonance imaging findings of internal derangement and effusion in patients with unilateral temporomandibular joint pain. Oral Surg Oral Med Oral Pathol Oral Radiol Endod 2001;92:566-71.
19. Emshoff R, Innerhofer K, Rudisch A, Bertram S. The biological concept of "internal derangement and osteoarthrosis": A diagnostic approach in patients with temporomandibular joint pain? Oral Surg Oral Med Oral Pathol Oral Radiol Endod 2002;93:39-44.
20. Shaefer JR, Jackson DL, Schiffman EL, Anderson QN. Pressure-pain thresholds and MRI effusions in TMJ arthralgia. J Dent Res 2001;80:1935-9.
21. Emshoff R, Brandlmaier I, Bertram S, Rudisch A. Relative odds of temporomandibular joint pain as a function of magnetic resonance imaging findings of internal derangement, osteoarthrosis, effusion, and bone marrow edema. Oral Surg Oral Med Oral Pathol Oral Radiol Endod 2003;95:437-45.